

# Extracorporeal Shock Wave Therapy (ESWT) in Patients with Tennis Elbow and Painful Heel

Dietrich S. Hammer, Stefan Rupp, Romain Seil, Stefan Ensslin, Dieter Kohn

**Abstract.** **Objective.** The aim of this study was to evaluate the effect of higher energy levels of extracorporeal shock wave therapy (ESWT) in tennis elbow and painful heel.

**Methods.** Nineteen patients with tennis elbow and 44 patients with painful heel in which conservative treatment had failed underwent ESWT. Three times 3000 shock waves in three successive weekly sessions were applied with an energy density of 0,12 mJ/mm<sup>2</sup> per shock wave.

**Results.** After a follow up of 5 respectively 6 months pain measured on a visual analogue scale (VAS) decreased significantly in both groups. The success rate (excellent and good results) was 63% in tennis elbows and 70% in painful heels.

**Conclusion.** ESWT seems to be a useful conservative alternative in the treatment of both conditions. Higher energy levels do not lead to a better outcome.

Key Index Terms: Extracorporeal shock wave therapy, tennis elbow, painful heel

Orthopaedic University Hospital, Homburg/Saar, Germany

For more than 15 years shock waves were successfully used in urology to desintegrate kidney and ureteric stones. The procedure was then applied in gastroenterology for the treatment of stones located in the gallbladder, common bile duct or pancreas and in oto-rhino-laryngology for the treatment of salivary stones.

In 1991 the method was practiced for the first time in the musculoskeletal system in pseudarthrosis <sup>(1,2,3)</sup>. Since then the extracorporal shock wave therapy (ESWT) showed encouraging results in the treatment of soft tissue pain <sup>(4,5)</sup> especially calcifying tendinitis of the shoulder <sup>(6,7,8)</sup>, chronic pain at the elbow <sup>(9)</sup> and heel <sup>(10,11)</sup>. Despite the long history of this method there are still many questions unanswered mainly regarding the mechanism of the effect, the dosage, and long term effects <sup>(12)</sup>.

The shock wave itself is a non linear high pressure impulse. It is characterized by an extremely high increase of pressure, a high maximum of pressure, a steep decrease of pressure with subsequent negative pressure wave. To induce the shock wave there are different principles in use: electro-hydraulic, electro-magnetic and piezo-electric systems. The shock wave is defined by following physical details: focus geometry (length and diameter [mm]), focus pressure maximum [bar] and focus energy density [mJ/mm<sup>2</sup>].

The focus energy density is nowadays used to compare treatment protocols of ESWT performed with machines of different induction principles. Arbitrarily the treatment levels were classified in low energetic (0,04 to 0,12 mJ/mm<sup>2</sup>) and high energetic (more than 0,12 mJ/mm<sup>2</sup>).

The aim of this study was to evaluate the effect of ESWT in patients with tennis elbow and painful heel treated with energy densities at the borderline from low to high energy levels without anaesthesia.

## **Materials and Methods**

Between December 1997 and November 1998 nineteen patients with epicondylitis humeri radialis (tennis elbow) and 44 patients with a painful heel (calcaneal) spur underwent low energy extracorporeal shock wave therapy (ESWT) in a prospective study at the Orthopaedic University Hospital, Homburg/Saar, Germany. In one case with painful heel spur we could not obtain post therapy results.

We included patients treated conservatively unsuccessfully at least 3 months. The treatment consisted of local and systemic antiinflammatories, local steroid injections, electro-therapy and physiotherapy. Typical pain had to be elicited by palpation at the lateral humeral epicondyl and with typical provocation tests (resisted wrist extension and middle finger extension) and at the radiologically proved calcaneal spur respectively.

We excluded patients with coagulation disorders, pregnancy, tumor in the area of treatment and neurologic disorders.

The extracorporeal shock wave therapy (ESWT) was performed with the experimental device Piezoson 300 (Richard Wolf, Knittlingen, Germany), a piezo-electric system with ultrasound detection (Fig. 1). Three times 3000 shock waves were applied over three consecutive weeks (3000 shock waves per weekly setting).

The group of patients with tennis elbow consisted of 8 women and 11 men with an average age of 46,4 years. They underwent conservative treatment for at least 6 months in all cases. The average energy density of a shock wave was 0,12 mJ/mm<sup>2</sup> (min 0,07 mJ/mm<sup>2</sup>, max 0,17 mJ/mm<sup>2</sup>). Follow up was done after 6 months (min 2 months, max 10 months).

Fourty-three of 44 patients with painful heel pain could be followed up. There were 29 women and 14 men (average age 53,9 years). The duration of symptoms and conservative therapy in one case was 3 months in all other cases more than 6 months. The average energy density of a shock wave was 0,12 mJ/mm<sup>2</sup> (min 0,07 mJ/mm<sup>2</sup>, max 0,16 mJ/mm<sup>2</sup>). Follow up was done after 5 months (min 1,5 months, max 11 months).

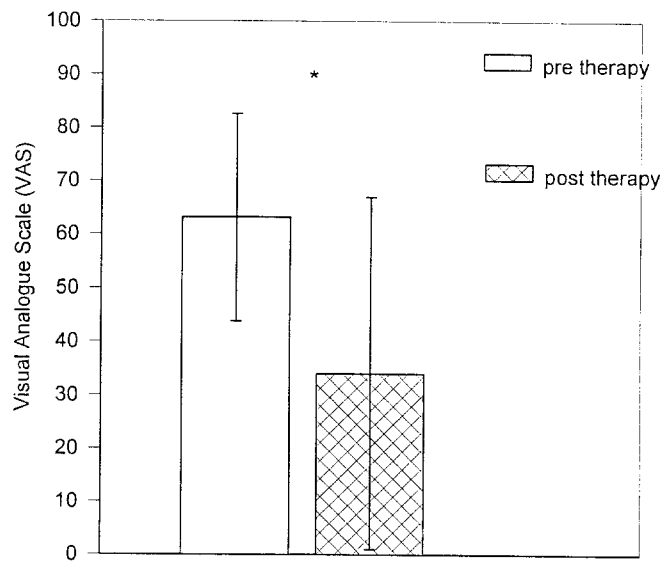
Before ESWT and at the above mentioned follow up pain intensity was estimated by the patient on the visual analogue scale (VAS) ranging from no pain (0) to maximal pain (100). In additon patients should state their satisfaction with the result afterwards ranging from excellent, good, moderate to bad. Statistical analysis was done with the Wilcoxon test a non parametrical test for paired samples.

## **Results**

In patients with tennis elbow (19 cases) the average pre-treatment VAS for pain was 63,2 (SD 19,4). At follow up after 6 months the VAS yielded 34,0 (SD 33,0). This decrease was significant with  $p < 0,01$  (Fig. 2). The individual improvement [%] of the VAS after therapy is shown in Fig. 3. In 9 cases (47%) the decrease was 61% to 100%, in 7 cases (37%) there was no improvement or worsening.

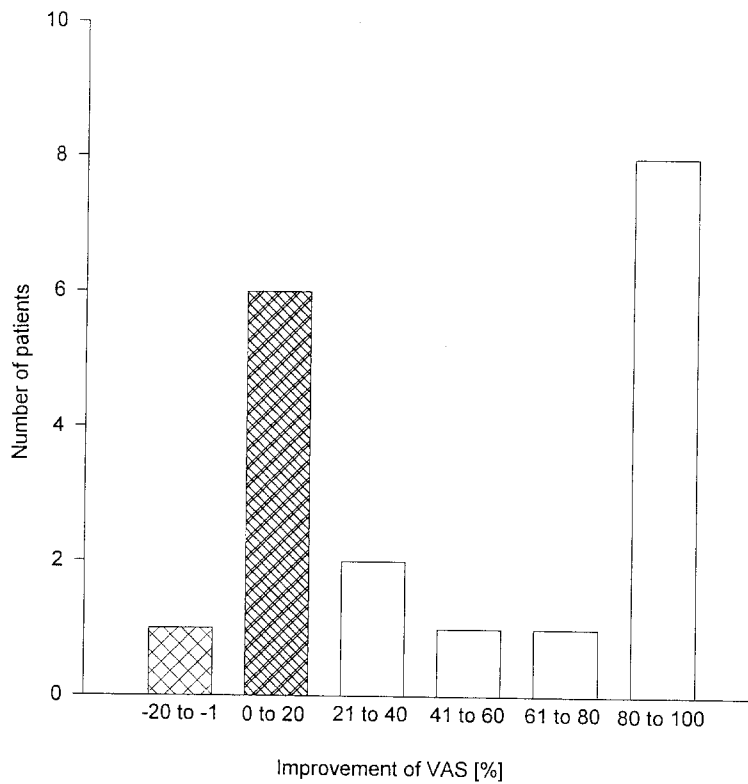
Regarding their satisfaction with the result 5 patients voted excellent (26%), 7 good (37%). In 3 cases (16%) the result was stated as moderate and the remaining 4 patients (21%) voted bad.

**Fig. 2** Visual Analogue Scale (VAS) in 19 patients with tennis elbow before and 6 months after ESWT  
\*  $p < 0.01$  (Wilcoxon test)



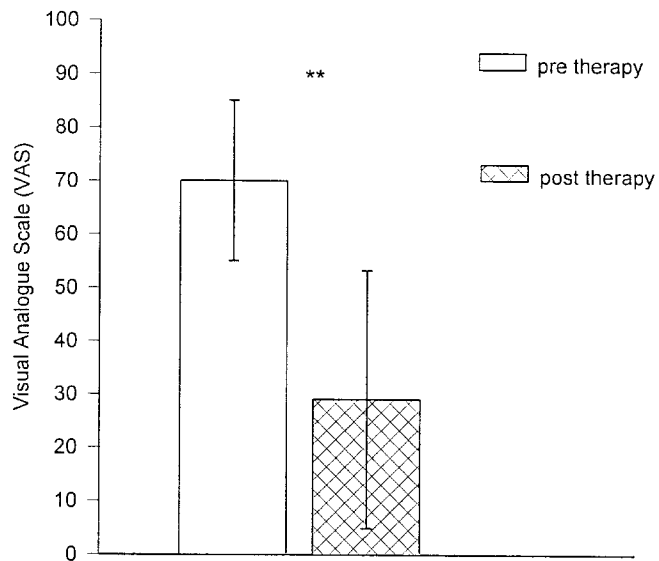
**Fig. 3** Improvement [%] of visual analogue scale (VAS) in 19 patients with tennis elbow 6 months after ESWT

▨ no benefit



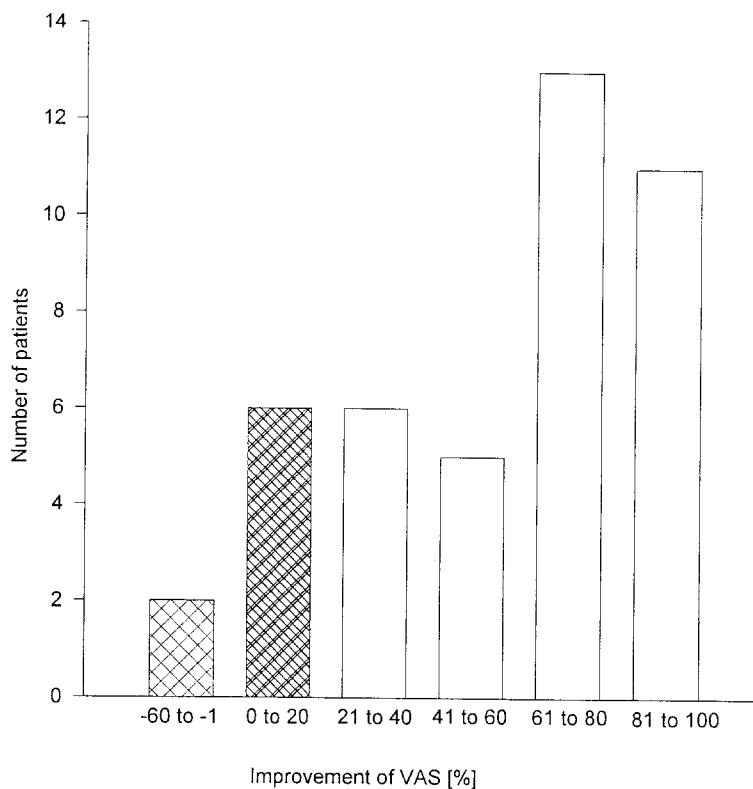
The pre-treatment VAS in the group of patients with painful heel (43 cases) was 70,1 (SD 15,0) in average. After 5 months the pain measured on the VAS reduced with  $p < 0,001$  significantly to 29,1 (SD 24,2) (Fig. 4). Fig. 5 shows the individual development of the VAS in percent. Twenty-four cases (56%) improved by 61% to 100%, 8 cases (19%) did no change or worsened. 13 patients (30%) judged the result as excellent, 17 as good (40%). The other patients voted moderate (6 cases; 14%) and bad (7 cases; 16%).

**Fig. 4** Visual Analogue Scale (VAS) in 43 patients with painful heel before and 5 months after ESWT  
\*\*  $p < 0.001$  (Wilcoxon test)



**Fig. 5** Improvement [%] of visual analogue scale (VAS) in 43 patients with painful heel 5 months after ESWT

▨ no benefit



## Discussion

Although the tennis elbow was described for the first time as “writer’s cramp” in 1873 by Runge <sup>(13)</sup> the knowledge of its etiology and pathology is still vague. It is believed to be an overuse syndrome due to repetitive tension overloading of the wrist extensor origins at the lateral epicondyle. Nevertheless various means of conservative treatment including physiotherapy, stretching, immobilisation, non steroidal antiinflammatories and steroid injections are recommended before a



surgical approach is considered. Various techniques are described with improvement rates of more than 80% <sup>(14,15)</sup>.

ESWT for tennis elbows as an alternative to surgery after conservative treatment has failed was described by different authors with different protocols. Rompe et al. <sup>(16)</sup> treated with 3x1000 shock waves of 0,06 mJ/mm<sup>2</sup> and reported a success rate (excellent and good results) of 73% after 6 months follow up. With 3x1000 shock waves of 0,08 mJ/mm<sup>2</sup> they reached success rates of 56% and 48% after 3 and 6 months follow up respectively <sup>(17,9)</sup>. Krschek et al. <sup>(18)</sup> achieved with 3x500 shock waves of 0,08 mJ/mm<sup>2</sup> a success rate of 60% after 6 months.

Painful heel is a common complaint in the foot of the elderly. The exact cause is unknown but predisposing factors like high age, obesity, plain foot, increased pronation of the foot, calcaneal spur may aggravate exerting stress on the origin of the plantar fascia at the medial process of the calcaneal tuberosity. Numerous conservative treatments were proposed and surgical treatment in case of failure promises up to 80% satisfactory results <sup>(19,20)</sup>.

ESWT in conservatively unsuccessfully treated patients was carried out with different protocols. Rompe et al. achieved with 3x1000 shockwaves of 0,08 mJ/mm<sup>2</sup> a success rate of 48% after 6 months <sup>(21)</sup> with 3x1000 shock waves of 0,06 mJ/mm<sup>2</sup> a success rate of 77,3% after 24 months <sup>(10)</sup>. Krschek et al. <sup>(11)</sup> reached a success rate of 58% with 3x500 shock waves of 0,08 mJ/mm<sup>2</sup> (follow up 12 months).

The painful process of both conditions is a local inflammatory reaction which leads to stimulation of the CNS via ascending pain pathways. It is believed that hyperstimulation of the painful spot by shock waves causes activation of descending inhibitory fibers on brain stem level. This could lead to a control of transmission through the dorsal horns as well as at higher levels in the somatic projection system

and thus to suppression of pain. The longlasting pain relief after a short period of hyperstimulation could be due to a change of pathologic moving patterns <sup>(22)</sup>.

Our results with success rates (excellent and good outcome) of 63% in patients with tennis elbow and 70% in patients with painful heel match the above quoted literature. The individual response in tennis elbows (Fig. 3) showed a bimodal pattern: ESWT either resolved the pain completely or did not work at all. In painful heels the individual response curve (Fig. 5) presented a high peak of total and subtotal improvement but also gradual responses. In our study the overall energy density was higher than in other the published data. The results do not indicate that higher energy levels improve the success rate significantly. ESWT seems to be useful as a conservative alternative in so far unsuccessfully treated patients with tennis elbow or painful heel. Further studies in similar conditions of the musculoskeletal system should be performed to open the method for other indications.

## References

1. Ekkernkamp A. Die Wirkung extrakorporaler Stoßwellen auf die Frakturheilung - eine tierexperimentelle Studie. Habilitationsschrift der Ruhr-Universität Bochum; 1991
2. Valchanou VD, Michailov P. High energy shock waves in the treatment of delayed and nonunion of fractures. *Int Orthop* 1991;15:181-184
3. Schleberger R, Senge T. Non-invasive treatment of long bone pseudarthrosis by shock waves (ESWL). *Arch Orthop Trauma Surg* 1992;111:277-287

4. Dahmen GP, Meiss L, Nam V, Cruodis B. Extrakorporale Stoßwellentherapie im knochennahen Weichteilbereich an der Schulter. *Extr Orthop* 1992;15:25-27
5. Haist J, Keitz-Steeger D. Stoßwellentherapie knochennaher Weichteilschmerzen - Ein neues Behandlungskonzept. In:Chaussy C, Eisenberger F, Jochum D, Wilbert D (Hrsg). *Die Stoßwelle - Forschung und Klinik*. Tübingen: Attempto Verlag; 1995:162-165
6. Loew M, Jurgowski W. Erste Erfahrungen mit der extrakorporellen Stoßwellenlithotripsie (ESWL) in der Behandlung der Tendinosis calcarea der Schulter. *Z Orthop* 1993;131:470-473
7. Loew M, Jurgowski W, Mau HC, Thomsen M. Treatment of calcifying tendinitis of rotator cuff by extracorporeal shock waves: A preliminary report. *J Shoulder Elbow Surg* 1995;4(3):101-106
8. Rompe JD, Rumler F, Hopf C, Nafe B, Heine H. Extracorporeal shock wave therapy for calcifying tendinitis of the shoulder. *Clin Orthop* 1995;321:196-201
9. Rompe JD, Hopf C, Küllmer K, Heine J, Bürger R. Analgetic effect of extracorporeal shock wave therapy on chronic tennis elbow. *J Bone Joint Surg* 1996;78-B:233-237
10. Rompe JD, Hopf C, Nafe B, Bürger R. Low energy extracorporeal shock wave therapy for painful heel: a prospective controlled single-blind study. *Arch Orthop Trauma Surg* 1996;115:75-79
11. Kricshek O, Rompe JD, Herbsthofer B, Nafe B. Symptomatische niedrig-energetische Stoßwellentherapie bei Fersenschmerzen und radiologisch nachweisbarem plantaren Fersensporn. *Z Orthop* 1998;136:169-174
12. Rompe JD. Stoßwellentherapie: Therapeutische Wirkung bei spekulativem Mechanismus. *Z Orthop* 1996;134:13-19

13. Runge F. Zur Genese und Behandlung des Schreibkrampfes. Berl Klin Wchnschr 1873;10:245-248
14. Demmer PJ, Rettig H. Degenerative Erkrankungen und Osteonekrosen. In: Witt AN, Rettig H, Schlegel KF (Hrsg). Orthopädie in Praxis und Klinik. Stuttgart-New York: Georg Thieme-Verlag;1982:6.7-6.11
15. Wright PE. Shoulder and elbow injuries. In:Crenshaw AH (ed). Campbells Operative Orthopaedics. St Louis-Washington-Toronto: The CV Mosby Company;1987:2515-2519
16. Rompe JD, Hopf C, Küllmer K, Witzsch U, Nafe B. Extrakorporale Stoßwellentherapie der Epicondylopathia humeri radialis - ein alternatives Behandlungskonzept. Z Orthop 1996;134:63-66
17. Rompe JD, Hopf C, Küllmer K, Heine J, Bürger R, Nafe B. Low-energy extracorporal shock wave therapy for persistent tennis elbow. Int Orthop 1996;20:23-27
18. Krischek O, Rompe JD, Hopf C, Vogel J, Herbsthofer B, Nafe B, Bürger R. Die extrakorporale Stoßwellentherapie bei Epicondylitis humeri radialis oder ulnaris - Eine prospektive, kontrollierte, vergleichende Studie. Z Orthop 1998;136:3-7
19. Schreiber A, Zollinger H. Entzündliche Erkrankungen des Fußes unter besonderer Berücksichtigung des polyarthritischen und gichtigen Fußes. In: Witt AN, Rettig H, Schlegel KF (Hrsg). Orthopädie in Praxis und Klinik. Stuttgart-New York: Georg Thieme-Verlag;1985:4.41-4.45
20. Richardson EG. The foot in adolescents and adults. In:Crenshaw AH (ed). Campbells Operative Orthopaedics. St Louis-Washington-Toronto: The CV Mosby Company;1987:933-937

21. Rompe JD, Küllmer K, Eysel P, Riehle HM, Bürger R, Nafe B.

Niedrigenergetische extrakorporale Stoßwellentherapie (ESWT) beim plantaren  
Fersensporn. Orthop Praxis 1996;32,4:271-275

22. Melzack R. Prolonged relief of pain by brief, intense transcutaneous somatic  
stimulation. Pain 1975;1:357-373